

## Chronic Venous Disease Treated by Ultrasound Guided Foam Sclerotherapy

P. Coleridge Smith\*

UCL Medical School, London, UK

**Aim.** To report the outcome of a series of patients with chronic venous disease due to incompetence of saphenous trunks managed by ultrasound guided foam sclerotherapy (UFS).

**Patients and methods.** A group of 808 patients comprise this series. CEAP clinical class for limbs was C1: 15%, C2: 81%, C3: 0.5%, C4: 2%, C5: 0.2%, C6: 0.4%. UFS using 1% polidocanol (107 limbs), 1% sodium tetradecyl (102 limbs), 3% sodium tetradecyl (900 limbs) was employed to treat incompetent saphenous trunks. In patients with unilateral varices 1 treatment was required in 43% of patients and 2 treatments in 48% of patients to obliterate incompetent saphenous trunks and varices. For bilateral varices 2 treatments were required in 40% of patients and 3 treatments in 46% of cases. The clinical outcome and patency of treated veins on duplex ultrasonography was assessed at a mean follow-up interval of 11 months.

**Results.** A total of 459 limbs were available for assessment at a follow-up interval of 6 months or greater. The CEAP clinical stage was C0:182 limbs, C1: 241, C2: 22, C3: 0, C4: 11, C5: 2, C6:1. The GSV had remained obliterated in 88% of limbs and the SSV in 82% of limbs. Recurrent venous incompetence following previous surgery was as effectively treated by UFS as primary incompetence.

**Conclusions.** This technique is useful in the management of chronic venous disease as an alternative to surgery.

**Keywords:** Varicose veins; Foam sclerotherapy; Duplex ultrasonography; Clinical outcome.

### Introduction

Surgery for varicose veins is widely used in the UK but recurrence may be expected in 25–50% of patients at 5 years.<sup>1–4</sup> Surgery leaves scars and may result in damage to adjacent structures including nerves, lymphatics, major arteries and veins.<sup>5</sup> Deep vein thrombosis and pulmonary embolism occur.<sup>6,7</sup> Saphenous trunks, but not superficial varices, may be obliterated by radiofrequency obliteration (RF obliteration)<sup>8</sup> or endovenous laser treatment (EVLT).<sup>9</sup> Phlebectomy or sclerotherapy are used to manage the residual varices. The advantage of using these methods is more rapid post-operative recovery compared to surgery.

In 1995 Cabrera reported that foam created using 'physiological gases' mixed with polidocanol (a detergent sclerosant) was effective in the management of truncal saphenous incompetence.<sup>10</sup> He used ultrasound guided injection into saphenous trunks.

Subsequently a number of authors have published clinical series using this treatment including Frullini and Cavezzi who reported a series of 453 patients<sup>11</sup> and Barrett who reported a series of 100 limbs.<sup>12</sup> Cavezzi has subsequently reported a good outcome in 93% of 194 patients.<sup>13</sup> This technique has become widely used in southern Europe, Australia, New Zealand, South America and the USA.<sup>14</sup> In the UK one series has been recently reported involving 60 patients comparing surgical treatment with foam sclerotherapy combined with sapheno-femoral ligation.<sup>15</sup>

The aim of this paper is to report the author's own series of patients treated by ultrasound guided foam (UFS) sclerotherapy for the management of chronic venous disease.

### Methods

A total of 808 patients (666 women, 142 men) were managed by ultrasound guided foam sclerotherapy for chronic venous disease due to truncal saphenous incompetence. Patients without truncal incompetence have been excluded from this series.

\*Corresponding author. Philip Coleridge Smith, DM, FRCS, Department of Surgery, Thames Valley Nuffield Hospital, Wexham Street, Wexham SL3 6NH, UK. Tel.: +44 1753 665449; fax: +44 1753 663964. E-mail address: p.coleridgesmith@ucl.ac.uk

All patients were referred to the author for management of varices in private practice (Thames Valley Nuffield Hospital, Wexham, Bucks, UK). Patients were assessed by clinical examination during which the CEAP clinical stage was recorded and all underwent colour duplex ultrasonography (Sonoline, Siemens, Germany) using a 5–9 MHz linear transducer. The author or an assistant trained in venous duplex ultrasound examination undertook all investigations. Patients stood during ultrasound examination and venous reflux was assessed by manual compression of the calf followed by release. Reverse flow in the vein under examination exceeding 0.5 seconds indicated venous incompetence.<sup>16</sup> The diameter of incompetent saphenous veins and perforating veins was recorded in a computer database. The extent of previous varicose vein surgery and recurrent varices shown by duplex ultrasound was also recorded. The definition of 'recurrent' used here is a saphenous trunk or system where previous junction ligation or stripping had been carried out. Limbs in which surgery had been carried out to another vein e.g. previous SSV surgery in a patient with GSV reflux, were classified as 'primary GSV reflux'. Incompetence of the anterior accessory saphenous vein (AASV) in limbs where previous GSV surgery had been performed was considered to be recurrent reflux according to recent anatomical definitions.<sup>17</sup>

All treatments were carried out in a consulting room without sedation or general anaesthesia using techniques based on those published by Cabrera.<sup>18</sup> The great saphenous vein (GSV) was cannulated with an 18g IV cannula (Optiva 2, Medex Medical Ltd, Rossendale, UK) at the level of the knee or just above with ultrasound guidance. The GSV below the knee was injected via a 23 g Butterfly needle (Abbot Ireland, Sligo, Eire). In the small saphenous vein the cannula was placed in the proximal part of the calf 10–15 cm from the sapheno-popliteal junction. The distal SSV was injected using a 23 g Butterfly. Correct positioning of the cannula or Butterfly was confirmed by the injection of 0.9% saline solution. Saphenous varices (3 mm diameter or greater) were injected through either a 23 g Butterfly or 30 g needle attached to a 2 ml syringe. Transverse ultrasound images of the veins were used to guide injections.

The Tessari method of preparing foam was used in which sclerosant and air was mixed in two syringes connected by a three-way tap.<sup>19</sup> The sclerosants used were either polidocanol (POL – Sclerovein<sup>®</sup>, Resinag AG, Zurich, Switzerland) and purified sodium tetradecyl sulphate (STD – Fibrovein<sup>®</sup>, STD Pharmaceuticals Ltd, Hereford, UK). POL was used as a 1% solution to create the foam to treat saphenous

trunks and STD was used as either a 1% or 3% solution for saphenous trunks. Foam was prepared in a ratio of 0.5 ml of sclerosant to 1.5 ml of air in keeping with previous publications.<sup>11</sup>

### Treatment of Patients

The author's preparation for this clinical series included treating 50 patients in clinical trials under the supervision of an experienced practitioner of ultrasound guided foam sclerotherapy. The author also has 20 years of experience of vascular duplex ultrasonography. Patients lay supine during cannulation of the veins and during treatment to minimise the amount of blood in the vein and to avoid syncope. With all cannulae and Butterflies in place the limb to be treated was elevated to an angle of about 30° to empty the veins and foam was injected. The progress of foam was monitored using ultrasound imaging. No specific measures were taken to avoid foam entering the deep veins but only 2 ml of foam per injection was given at a time. The total amount of foam injected in one treatment session was limited to 20 ml in order to avoid local or systemic complications. Saphenous trunks were injected first and any residual varices treated in subsequent sessions. Blood flow in the deep veins was encouraged after each injection by asking the patient to perform a series of dorsiflexions at the ankle in order to minimise the risk of DVT.

Prophylactic heparin was not given routinely in this series. A small number of patients with duplex ultrasound evidence of post-thrombotic deep vein damage was treated. All received a 5 day course of prophylactic LMWH and none developed a DVT.

Short stretch compression bandaging was applied to limbs where saphenous trunks and varices had been injected. Pehahaft cohesive bandage (Pehahaft<sup>®</sup>, Hartmann, Germany) was used with Velband (Velband<sup>®</sup>, Johnson & Johnson Medical, Ascot, Berkshire, UK) cotton wool padding applied over the saphenous trunks to increase compression. A class 2 medical compression stocking was measured and applied over the bandage to secure the bandage (Credelast<sup>®</sup>, Credenhill, Ilkeston, Derbyshire, UK). Initially bandaging was left in place for 3–5 days but later in the series this was increased to 10–14 days to minimise the incidence of thrombophlebitis. Treatment sessions were carried out at intervals of 2 weeks. Duplex ultrasonography was used to check the treated veins for completeness of occlusion. Veins containing a substantial amount of residual thrombus after sclerotherapy were managed by aspiration using a 19 g needle.

Patients were invited to return for follow up visits 6 months after treatment. The patients were asked about symptoms and recurrence of varices. The CEAP clinical stage was recorded at each visit and duplex ultrasonography used to assess the state of occlusion of saphenous trunks and varices. In addition, the competence of all other saphenous trunks and deep veins of the thigh and calf were assessed.

Where recurrent or residual reflux was found in tributaries or trunks, further UFS was used. The diameter of recurrent incompetent saphenous trunks following earlier foam sclerotherapy was much smaller than at the initial treatment. Subsequent foam sclerotherapy was no more technically complex than at the first treatment and usually resulted in obliteration of the re-treated saphenous trunk. Longer term follow-up in retreated saphenous trunks has not been completed. No patient required surgical treatment.

### Statistical Analysis

Data are represented by the mean and range for the age and median and interquartile range for all other data, which were not normally distributed. Tests of statistical significance have not been used. These were not considered appropriate in a clinical series where differences may have arisen as a consequence of differences in treatment policy.

### Results

A total of 808 patients are included in this series in whom 1411 limbs were affected by venous disease. The clinical and duplex ultrasound findings are summarised in Table 1. The overwhelming majority of limbs were affected by uncomplicated varicose veins (CEAP C2,  $n = 1154$ , 81%) attributable to GSV or SSV

reflux but patients from all CEAP clinical stages are included. Some saphenous trunks shown to be incompetent on duplex ultrasound were not treated since they gave rise to few or no varices. In all 1109 limbs were managed by foam sclerotherapy. A surprisingly high proportion of patients had undergone previous surgery for varicose veins in the vessel being treated, 30% of GSVs and 17% of SSVs. Four limbs were treated in which post-thrombotic deep vein incompetence was found in association with GSV or SSV reflux.

Table 2 summarises the number of treatments that were performed in all 808 patients to obliterate incompetence trunks and varices. In 99% of patients with unilateral varices and 92% of bilateral varices 3 treatments were sufficient to obliterate all veins. The median volume of sclerosant foam required to achieve this outcome over all sessions was 14 ml (interquartile range, IQR 9–21 ml, range 1 ml–72 ml). The median volume of foam used per limb over all sessions was 10 ml (IQR 6–14 ml). In treating the GSV the median volume of foam used was 10 ml (IQR 6–14 ml) and for the SSV 6 ml (IQR 5–10 ml).

Initially in this series, 1% POL foam was used to treat saphenous trunks. Later 1% and 3% STD were employed. The aim of using stronger sclerosants was to minimise the risk of recanalisation of saphenous trunks. 1% POL was used in 13% of saphenous veins, 1% STD in 9% and 3% STD in 78%.

Thrombophlebitis occurred in a small number of patients (5%) and was managed by analgesia, compression and aspiration of thrombus. Calf vein thrombosis was confined to isolated gastrocnemius veins or to part of the posterior tibial vein (10 cases). All resolved with compression by stocking or bandage and exercise without use of anticoagulants. In one case a short occlusive thrombus arose in the common femoral vein 2 weeks following treatment of the GSV

**Table 1. Patients included in study – clinical data**

Total number of patients					
Men	$n = 142$	Mean age: 56	range: 17–95		
Women	$n = 666$	Mean age: 52	range: 19–91		
CEAP stage – limbs with venous disease considered for treatment, total 1411					
C1	C2	C3	C4a + C4b	C5	C6
212 (15%)	1154 (81%)	6	29 (2%)	3	7
Duplex ultrasound findings in 1109 limbs which were treated by UFS					
GSV reflux, alone	766 (69%)				
SSV reflux, alone	223 (20%)				
GSV and SSV reflux	120 (11%)				
Primary GSV reflux	618	Recurrent GSV reflux	267 (30% of GSVs)		
Primary SSV reflux	283	Recurrent SSV reflux	60 (17% of SSVs)		
Median GSV diameter	5 mm (IQR 4–6), range 1–18 mm				
Median SSV diameter	5 mm (IQR 4–6), range 1–12 mm				

**Table 2. Number of treatments received per patient**

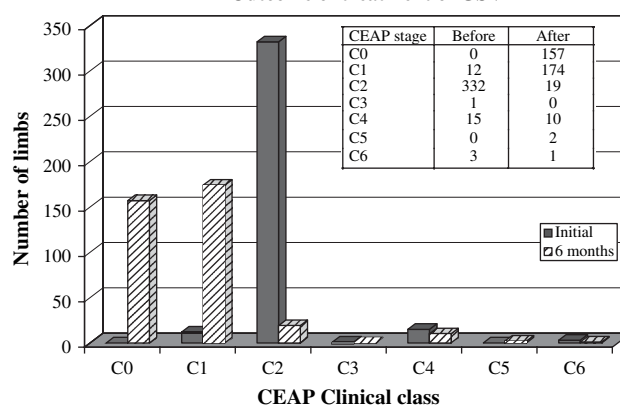
Patient analysis	Unilateral varices	Bilateral varices
1 treatment	187 (43%)	20 (6%)
2 treatments	207 (48%)	153 (40%)
3 treatments	34 (8%)	173 (46%)
>3 treatments	3 (1%)	31 (8%)

probably due to direct extension of thrombus from the GSV into the femoral vein. This case was managed by anticoagulation using low molecular weight heparin and warfarin continued for six months. The occluded femoral vein recanalised within 4 weeks and at six months of follow-up no residual scarring or valve damage could be demonstrated on duplex ultrasonography. In two further cases non-occlusive thrombus extended from the SFJ and SPJ (one case each) into the femoral and popliteal vein. The extent of the thrombus was limited and firmly adherent to the vein wall. This was managed by compression stockings and exercise whilst monitoring the extent of the thrombus by duplex ultrasonography. In these cases the thrombus resolved without further intervention.

No major systemic complication such as anaphylaxis, stroke or transient ischaemic attack occurred in this series. A number of patients (14, 2% of all patients treated) reported visual disturbance following treatment. Patients with a previous history of migraine with visual aura were especially at risk of this problem. The visual aura was precipitated by sclerotherapy and resolved in most cases within 30 minutes. Patients experiencing one episode of visual disturbance were prone to further episodes. These patients were managed by inviting them to rest supine for 30 mins following treatment.

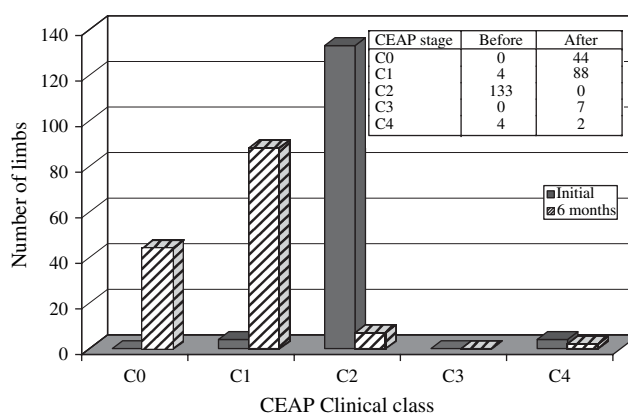
Although all patients were invited for follow-up examinations at 6 months following treatment, by no means all patients returned despite reminders. In all 459 limbs have been reviewed at 6 months or more following treatment, average 11 months, range 6–46 months. This includes 363 of 886 GSVs and 141 of 263 SSVs. Figs. 1 and 2 show the CEAP clinical class before and after sclerotherapy in these limbs. A substantial improvement in clinical venous disease was obtained. Duplex examination of the GSVs showed occlusion had been obtained in 318 of 363 (88%). In the SSVs occlusion was present in 116 of 141 (83%).

The data in Table 3 show the outcome of treatment for the GSV and SSV. Where incompetence or varices arose in a major tributary of the GSV or SSV this was also considered to comprise treatment failure. In 4 cases reviewed after 6 months the anterior accessory saphenous vein developed reflux and in one case a medial thigh tributary of the GSV was incompetent.

**Outcome of treatment of GSV****Fig. 1. CEAP clinical stage before and at an average of 11 months after UFS carried out to the GSV.**

The data in Table 3 has been subdivided to assess factors which might influence the outcome including diameter of the vein, type of sclerosant and whether primary or recurrent varices were treated. A greater incidence of recanalisation was seen in GSVs and SSVs larger than 5 mm in diameter. The recurrence rates are similar with both sclerosants used in the treatment. A substantial proportion (30%) of patients were treated for recurrent varices of the GSV following previous surgery. The outcome for this group was similar to that for patients with primary varices.

Residual skin pigmentation and palpable lumps were sometimes seen at follow-up. Skin pigmentation was seen in 115 of 459 limbs at 6 months and palpable lumps were present in 21 limbs. The skin pigmentation was almost always of a minor extent and continued to fade with time. 1 year or more following

**Outcome of treatment of SSV****Fig. 2. CEAP clinical stage before and at an average of 11 months after UFS carried out to the SSV.**

**Table 3. Outcome in 363 (of 886) GSVs and 141 (of 263) SSVs where follow-up had been completed at 6 months or more (mean 11 months following treatment)**

	Total examined	Vein status	
		Occluded	Incompetent
GSV	363	318 (88%)	45
GSV > 5 mm dia	160	130 (81%)	30
GSV ≤ 5 mm dia	203	189 (93%)	15
GSV treated POL	39	33 (80%)	6
GSV treated STD	324	285 (88%)	39
GSV primary	257	220 (86%)	37
GSV recurrent	106	98 (92%)	8
Median diameter	Before treatment 5 mm (IQR 4–6)	After treatment 2 mm (IQR 0–3)	
SSV	141	116 (82%)	25
SSV > 5 mm dia	62	48 (77%)	14
SSV ≤ 5 mm dia	79	68 (86%)	11
SSV treated POL	15	11 (73%)	4
SSV treated STD	126	105 (84%)	21
SSV primary	135	111 (82%)	24
SSV recurrent	6	5	1
Median diameter	Before treatment 5 mm (IQR 4–6)	After treatment 2 mm (IQR 1–3)	

treatment skin pigmentation was present in 11 of 115 limbs. Small palpable lumps were sometimes detectable in the calf and comprised residual elements of treated veins. In contrast to surgical series, no scars, neurological damage or lymphatic injuries were encountered.

### Discussion

The publication of a clinical series cannot replace a randomised controlled trial (RCT) in the evaluation of a new treatment. The author acknowledges one RCT has been published, however both groups of patients underwent surgical ligation of the SFJ with sclerosant foam or stripping being used to manage the saphenous trunk.<sup>15</sup> A further randomised clinical trial of Varisolve<sup>®</sup>, a polidocanol foam, compared against surgery in 650 patients has been completed and reported at a scientific meeting (UIP Chapter meeting, San Diego, USA, 2003) but not yet published. The final endpoint is the efficacy with which a treatment eliminates varicose veins after an extended period of follow-up. Hobbs found that a follow-up period of 10 years was required fully to distinguish the failures of injection-compression treatment from surgery.<sup>20</sup> Such long studies are difficult to complete and many authors now base their conclusions on the use of duplex ultrasound imaging as a surrogate endpoint. There is a good correlation between duplex recurrence at the SFJ 1 year after treatment and clinical recurrence 5 years after treatment.<sup>21</sup> Duplex ultrasonography has been used as a predictor of the final outcome of treatment in this series.

Varicose vein surgery is imperfect. Neurological injury and an unsatisfactory outcome are common causes for litigation, damage to the femoral artery and vein also occurs.<sup>5</sup> Rautio found that patients undergoing varicose vein surgery required on average 16 days off work compared to 6.5 days following RF closure of the saphenous trunk.<sup>22</sup> Recurrence of varicose veins following surgery is a common event and is often attributable to neovascularisation.<sup>21,23,24</sup> Fischer reviewed 125 limbs in 77 patients after an average of 34 years following SFJ ligation and GSV stripping and found recurrence in 60%.<sup>3</sup> Wood *et al.* reported that neurological injury may be present in 27% of patients treated surgically six weeks post-operatively.<sup>25</sup> Ouvry reports an 8.7% rate of lymphatic complications amongst 30 surgeons surveyed.<sup>26</sup> Surgical treatment which is widely regarded as the reference standard, carries the risk of significant post-operative complications, necessitates significant time off work and despite this does not prevent recurrence.

In my series foam sclerotherapy required 30 minutes per treatment session, patients could walk from the room afterwards and in most cases patients only took time off on the days in which treatment was given. Discomfort at the time of treatment was minimal and in the majority of patients, symptoms in the 2 weeks following treatment were few, although thrombophlebitis was seen in 5%. Patients main complaints related to the compression bandage applied after each session. Few other problems were encountered with skin pigmentation at follow-up being the most frequent. This was usually mild and continued to resolve with the passage of time.



Patients followed up for more than 6 months represent only 40% of the overall group. This is a potential disadvantage since it might lead to bias in the overall assessment. Patients were all invited to attend at an interval of 6 months following initial treatment but many defaulted. In some instances patients returned with residual or recurrent varices due to recanalisation of the treated vein. Further invitations for review have now been sent to those who have not attended so far at the planned 6 month interval.

Examination of Table 3 shows that the main factor influencing recurrence was the size of the vein prior to treatment. Both GSVs and SSVs of 6 mm dia or greater were more likely to recur than those of 5 mm dia and below. For the GSV, treatment of recurrent varicose veins was as successful as for primary varices. Operations for recurrent varicose veins are usually technically more difficult and prone to a high complication rate compared to that for primary varices.<sup>27</sup> Foam sclerotherapy carries little risk and may be a satisfactory solution in patients with recurrence following previous surgery.

In the series of patients presented here, no case of neovascularisation was seen at the SFJ or SPJ although this would have been expected following surgical treatment. The mode of recurrence following UFS was recanalisation of previously treated veins. It is likely that surgical treatment itself promotes neovascularisation. If varicose veins can be closed without surgical intervention then the risk of neovascularisation is minimised.

Comparison of UFS to other endovenous techniques reveals similar outcomes. In a series of 1006 patients treated by RF obliteration with follow-up to 5 years the occlusion rate for saphenous trunks was 88% at one year.<sup>28</sup> Endovenous laser treatment (EVLT) been reviewed recently.<sup>29</sup> In 13 clinical series 88 – 100% of treated saphenous trunks were obliterated. Reported complications of both techniques include skin burns, thrombosis, ecchymosis, paraesthesia, induration and phlebitis.

This clinical series demonstrates that ultrasound guided foam sclerotherapy can be used effectively to manage a wide range of chronic venous disease on an outpatient basis without the need to resort to surgical intervention. The efficacy and rates of complication are similar to those reported for the other 'new' treatments for varicose veins.

#### Acknowledgements

I am grateful to Attilio Cavezzi MD for introducing me to foam sclerotherapy and to David Wright FRCS for guidance concerning the technique. I acknowledge the valuable

assistance of the following members of my team for assistance in completing this work: Paola Buresta MD, Maria Cork RGN, Frances Devine RGN, Sue Topp RGN. I am also indebted to the many experts in venous disease who have provided advice in the preparation of this manuscript.

#### References

- 1 VAN RIJ AM, JIANG P, SOLOMON C, CHRISTIE RA, HILL GB. Recurrence after varicose vein surgery: a prospective long-term clinical study with duplex ultrasound scanning and air plethysmography. *J Vasc Surg* 2003;**38**:935–943.
- 2 WINTERBORN RJ, FOY C, EARNSHAW JJ. Causes of varicose vein recurrence: late results of a randomized controlled trial of stripping the long saphenous vein. *J Vasc Surg* 2004;**40**:634–639.
- 3 FISCHER R, LINDE N, DUFF C, JEANNERET C, CHANDLER JG, SEEBER P. Late recurrent saphenofemoral junction reflux after ligation and stripping of the greater saphenous vein. *J Vasc Surg* 2001;**34**:236–240.
- 4 PERRIN MR, GUEX JJ, RUCKLEY CV, DEPALMA RG, ROYLE JP, EKLOF B *et al*. Recurrent varices after surgery (REVAS), a consensus document. REVAS group. *Cardiovasc Surg* 2000;**8**:233–245.
- 5 CAMPBELL WB, FRANCE F, GOODWIN HM, Research and Audit Committee of the Vascular Surgical Society of Great Britain and Ireland. Medicolegal claims in vascular surgery. *Ann R Coll Surg Engl* 2002;**84**:181–184.
- 6 VAN RIJ AM, CHAI J, HILL GB, CHRISTIE RA. Incidence of deep vein thrombosis after varicose vein surgery. *Br J Surg* 2004;**91**:1582–1585.
- 7 SRILEKHA A, KARUNANITHY N, CORBETT CRR. Informed consent: what do we tell patients about the risk of fatal pulmonary embolism after varicose vein surgery? *Phlebology* 2005;**20**:175–176.
- 8 MERCHANT RF, PICHOT O, Closure Study Group. Long-term outcomes of endovenous radiofrequency obliteration of saphenous reflux as a treatment for superficial venous insufficiency. *J Vasc Surg* 2005;**42**:502–509.
- 9 MUNDY L, MERLIN TL, FITRIDGE RA, HILLER JE. Systematic review of endovenous laser treatment for varicose veins. *Br J Surg* 2005;**92**:1189–1194.
- 10 CABRERA GARIDO JR, CABRERA GARCIA OLMEDO JR, DOMINGUEZ GARCIA OLMEDO. Nuevo metododel de esclerosis en las varices tronculares. *Patologia Vasculares* 1995;**4**:55–73.
- 11 FRULLINI A, CAVEZZI A. Sclerosing foam in the treatment of varicose veins and telangiectases: history and analysis of safety and complications. *Dermatol Surg* 2002;**28**:11–15.
- 12 BARRETT JM, ALLEN B, OCKELFORD A, GOLDMAN MP. Microfoam ultrasound-guided sclerotherapy of varicose veins in 100 legs. *Dermatol Surg* 2004;**30**:6–12.
- 13 CAVEZZI A, FRULLINI A, RICCI S, TESSARI L. Treatment of varicose veins by foam sclerotherapy: two clinical series. *Phlebology* 2002;**17**:13–18.
- 14 BREU FX, GUGGENBICHLER S. European consensus meeting on foam sclerotherapy [April, 4-6, 2003, Tegernsee, Germany]. *Dermatol Surg* 2004;**30**:709–717.
- 15 BOUNTOUROGLOU DG, AZZAM M, KAKKOS SK, PATHMARAJAH M, YOUNG P, GEROUKAKOS G. Ultrasound-guided foam sclerotherapy combined with sapheno-femoral ligation compared to surgical treatment of varicose veins: early results of a randomised controlled trial. *Eur J Vasc Endovasc Surg* 2005.
- 16 VAN BEMMELN PS, MATTOS MA, HODGSON KJ, BARKMEIER LD, RAMSEY DE, FAUGHT WE *et al*. Does air plethysmography correlate with duplex scanning in patients with chronic venous insufficiency? *J Vasc Surg* 1993;**18**:796–807.
- 17 CAGGIATI A, BERGAN JJ, GLOVICZKI P, EKLOF B, ALLEGRA C, PARTSCH H *et al*. Nomenclature of the veins of the lower limb: extensions, refinements, and clinical application. *J Vasc Surg* 2005;**41**:719–724.

- 18 CABRERA J, CABRERA Jr J, GARCIA-OLMEDO MA. Treatment of varicose long saphenous veins with sclerosant in microfoam form: long term outcomes. *Phlebology* 2000;**15**:19–23.
- 19 TESSARI L. *Nouvelle technique d'obtention de la scléro-mousse Phlébologie* 2000;**53**:129.
- 20 HOBBS JT. Surgery or sclerotherapy for varicose veins: 10-year results of a random trial. In: TESI M, DORMANDY JA, eds. *Superficial and deep venous diseases of the lower limbs*. Turin: Panminerva Medica; Sept 1984:243–248.
- 21 DE MAESENEER MG, VANDENBROECK CP, HENDRIKS JM, LAUWERS PR, VAN SCHIL PE. Accuracy of duplex evaluation one year after varicose vein surgery to predict recurrence at the sapheno-femoral junction after five years. *Eur J Vasc Endovasc Surg* 2005;**29**:308–312.
- 22 PERALA J, RAUTIO T, BIANCARI F, OHTONEN P, WIIK H, HEIKKINEN T *et al*. Radiofrequency endovenous obliteration versus stripping of the long saphenous vein in the management of primary varicose veins: 3-year outcome of a randomized study. *Ann Vasc Surg* 2005;**19**:669–672.
- 23 SARIN S, SCURR JH, COLERIDGE SMITH PD. Assessment of stripping the long saphenous vein in the treatment of primary varicose veins. *Br J Surg* 1992;**79**:889–893.
- 24 VAN RIJ AM, JONES GT, HILL GB, JIANG P. Neovascularization and recurrent varicose veins: more histologic and ultrasound evidence. *J Vasc Surg* 2004;**40**:296–302.
- 25 WOOD JJ, CHANT H, LAUGHARNE M, CHANT T, MITCHELL DC. A prospective study of cutaneous nerve injury following long saphenous vein surgery. *Eur J Vasc Endovasc Surg* 2005;**30**: 654–658.
- 26 OUVRY PA, GUENEGUEZ H, OUVRY PAG. Complications lymphatiques de la chirurgie des varices. *Phlebologie* 1993;**46**:563–568.
- 27 HAYDEN A, HOLDSWORTH J. Complications following re-exploration of the groin for recurrent varicose veins. *Ann R Coll Surg Engl* 2001;**83**:272–273.
- 28 MERCHANT RF, PICHOT O, Closure Study Group. Long-term outcomes of endovenous radiofrequency obliteration of saphenous reflux as a treatment for superficial venous insufficiency. *J Vasc Surg* 2005;**42**:502–509.
- 29 MUNDY L, MERLIN TL, FITRIDGE RA, HILLER JE. Systematic review of endovenous laser treatment for varicose veins. *Br J Surg* 2005;**92**:1189–1194.

Accepted 27 April 2006